

ORIGINAL RESEARCH

PASSIVE ROTATION RANGE OF MOTION AND SHOULDER SUBLUXATION: A COMPARATIVE STUDY

Joel Buckler, BSc PT, Dip Man Ther, FCAMT^aWilliam Stanish, MD, FRCS(C), FACS^bCheryl Kozey, PhD^c

ABSTRACT

Background. Conflicting reports of range of motion (ROM) findings exist related to shoulder instability. Knowledge of range of motion findings among individuals with shoulder subluxation may aid in diagnosis and facilitate appropriate management.

Purpose. The purpose of this study was to compare passive rotation ROM and determine if a symptom-provoking activity alters ROM between patients with shoulder subluxations and healthy controls.

Methods. Seventeen symptomatic patients with shoulder subluxations and 14 healthy controls between the ages of 18 and 35 years were recruited. Lateral and medial rotation ROM measures were taken using a universal goniometer. Symptoms were assessed using a 10cm visual analog scale (VAS). Each group performed a symptom-provoking activity, and VAS and ROM measures were repeated.

Results. A two-factor analysis of variance with repeated measures on pre/post activity demonstrated lower medial rotation measures for the instability group, but no differences for lateral rotation or total range ($p < 0.05$). A "warm-up" effect was noted, with greater ROM found in each group post activity, with a greater increase noted among

controls. Analysis of the ratio of lateral rotation to medial rotation ROM found a significantly greater ratio in the instability group. VAS pain scores were greater in the instability group.

Conclusion. Shoulder subluxation is not necessarily associated with increased rotation ROM, therefore total ROM findings should not be used to screen for instability. Imbalances in rotation ROM may be associated with symptomatic shoulder instability and may have implications for treatment.

Key Words: atraumatic, instability, multidirectional

CORRESPONDENCE

Joel Buckler

Physiotherapy Dept., 2nd Floor VMB

Queen Elizabeth II Health Sciences Centre

Capital Health

5595 Veterans Memorial Lane

Halifax, Nova Scotia

B3H 2E1

E-mail: joel.buckler@cdha.nshealth.ca

Phone: (902)473-6308

ACKNOWLEDGEMENTS

The Authors would like to thank Tanya Dutton, Danielle LeBrun, and Gillian Hatfield for their assistance with this study.

GRANT SUPPORT

Sport Medicine Institute of Nova Scotia

Capital Health Centre for Clinical Research

^a Queen Elizabeth II Health Sciences Centre
Halifax, Nova Scotia; Canada

^b Orthopaedic and Sports Medicine Clinic of Nova Scotia
Halifax, Nova Scotia; Canada

^c Dalhousie University School of Physiotherapy and
Biomedical Engineering
Halifax, Nova Scotia; Canada

INTRODUCTION

Shoulder instabilities are classified based on the presence or absence of trauma, chronicity, volition, direction, and degree of instability.¹⁻³ Grading schemes have been developed to quantify degree of shoulder instability.⁴ Shoulder subluxation is also known in the literature as subtle shoulder instability, occult shoulder instability, and minor shoulder instability.⁵⁻⁷ The American Academy of Orthopaedic Surgeons broadly categorizes shoulder instability into two groups: Atraumatic, Multidirectional, Bilateral, Rehabilitation, and Inferior capsular shift (AMBRI) and Traumatic, Unidirectional, Bankart, Surgery (TUBS). These groupings are useful to help guide management. Not all shoulder instabilities fit clearly into these classifications. Shoulder subluxation is characterized by excessive translation of the head of the humerus on the glenoid surface and may involve hyperelasticity of the joint capsule and attenuation of the glenohumeral ligaments.⁸ Other authors suggest that tears of the glenoid labrum, loss of joint cohesion and compromise of supporting musculature may also be involved.^{7,9-12}

Symptoms reported with instability include: apprehension with certain movements, a sensation of “slipping out,” pain with overhead movements, catching, clunking, Dead Arm Syndrome, weakness, and loss of proprioception.^{1,11,13-16} Physical findings noted include: full or excessive range of motion (ROM), loose end feel, decreased lateral rotation ROM, positive apprehension sign, and resisted movements that are often strong and pain free.^{6,14,16} Jobe and Pink² have associated shoulder instability with generalized multi-joint laxity. Diagnosis of shoulder subluxation, in the absence of trauma, is made through clinical history and physical exam including instability tests such as the Load and Shift and the Relocation tests.⁸ No gold standard of investigation exists for identifying this condition.

Congenital hypermobility has been implicated in the etiology of shoulder instability.⁴ Many authors have related instability dysfunction of the shoulder to overhead athletic activity.^{2,4,5,7,13,14,16-21} Shoulder instability may often go undiagnosed due to a poverty of physical findings on examination.^{5,6,16} Differential diagnosis between instability and subacromial impingement is reportedly one of the most difficult in the shoulder region.²² Normative data on shoulder ROM measures active rather than passive ROM, does not report the assessment protocol, or measures ROM in very specific populations. No significant differ-

ence is noted between left- or right-sided ROM measures in studies on asymptomatic controls.^{19,23,24,25,26}

Conservative treatment of patients with shoulder instability may differ drastically from treatment of other shoulder conditions. Improper rehabilitation may perpetuate or exacerbate shoulder symptoms. Physical examination techniques to assess for shoulder instability can be difficult to perform and require significant experience to interpret correctly. The problems associated with diagnosis and the significant disability created by shoulder instability demonstrate the need for reliable clinical assessment tools to help identify this condition. Inter-rater reliability for passive lateral rotation “end-feel” has been demonstrated with a variety of shoulder pathologies.²⁷ Conflicting reports of ROM findings associated with shoulder instability raise the question of the efficacy of ROM findings in diagnosis.^{1,15} Range of motion may be altered by the presence of pain or other symptoms and this may obscure the relevance in examination findings. Passive rotation ROM assessment is a much less challenging evaluation procedure than stability testing the shoulder. A relationship between passive shoulder rotation ROM and subluxation may allow findings of ROM assessments to be used to guide further assessment/investigation in the direction of instability testing.

The purpose of the study was twofold: i) to determine if patients with shoulder subluxation have abnormal passive rotation ROM and ii) to assess if a symptom-provoking shoulder activity will alter ROM measures.

Our main null hypothesis was that no significant difference between passive range of motion measures would be found i) in symptomatic patients with shoulder subluxation and a group of healthy controls and ii) between pre and post symptom-provoking activity. Secondly, whether differences existed between the two groups and post symptom-provoking activity in VAS of pain/discomfort was tested.

METHODS

Thirty-one outpatient clients at the QEII Health Science Centre, University Physiotherapy Inc. and the Orthopaedic and Sports Medicine Clinic of Nova Scotia were recruited. The sample was chosen to detect a clinically significant difference in ROM ($\geq 7^\circ$) using variance measures from the literature at 0.05 level of significance with a power of 0.8.^{25,26,28} Intra-tester reliability for rotation

measures at the shoulder have been reported as excellent with intraclass correlation coefficients (ICC) of 0.88-0.98.^{28,29} Consent was obtained after participants received a study explanation and information regarding their rights as a participant in accordance with the Research Ethics Board of the Capital Health Centre for Clinical Research. Seventeen minimally to moderately symptomatic patients with shoulder subluxation, between the ages of 18 and 35 years were assigned to the instability group. Subjective inclusion criteria included complaints of pain with overhead movements, snapping and/or clicking, a sensation of the shoulder slipping out, and/or a position of apprehension. Participants were asked to rate their baseline intensity of shoulder pain/discomfort on a 10cm visual analog scale (VAS) with no descriptors, and scores of less than or equal to 4/10 were included. On objective examination, excessive translation of the head of the humerus on anterior stability testing at 90 degrees of abduction was observed. Assessment was performed for anterior load and shift, which is known to have good to excellent inter-examiner agreement with ICCs of 0.72-0.79.³⁰ Each shoulder met Hawkins Grade I-II classification for instability (*Figure 1*). History of dislocation without spontaneous reduction resulted in exclusion. Each subject met each of the diagnostic criteria to be included.

The control group consisted of healthy physiotherapy clients with no history of shoulder injury or dysfunction, between the ages of 18 and 35 years. They were randomly selected from those attending the QEII Health Sciences Centre. The study was described, and 14 agreed to participate. Their condition or reason for attendance to the QEII Health Sciences Centre could have no impact on shoulder function. A brief history was taken to ensure they had no current or previous shoulder pathology. These participants were assigned to a control group of asymptomatic healthy individuals.

The investigation was a comparative study between healthy subjects and those with

shoulder subluxation. The primary dependent measure was ROM in degrees. The secondary dependent measure was symptoms on a 10cm VAS. The VAS was chosen to represent only the level of discomfort/pain associated with their condition and the symptom-provoking activity performed in the evaluation and was not used to measure the impact of their condition or disability. The control group was evaluated following a full study explanation, including information regarding their rights as a participant. Signed consent was obtained along with descriptive data including age, height, mass, sex, and participation in overhead sporting activities as these factors have all been suggested to affect ROM measures.^{23,26} Samples were compared on these descriptive variables to ensure equal groups.

The control group shoulder (left or right) to be evaluated was randomly assigned with a coin toss. The humerus was manually stabilized at 90 degrees abduction and neutral flexion/extension by an examiner. The scapula was manually stabilized at the lateral border. Three repeated movements into lateral rotation were produced until a R2 end-point (a point at which increased force does not appear to increase range) was obtained (*Figure 2*). Each passive movement was sustained for 15 seconds and the measurement was taken on the third repetition using a universal goniometer. The procedure was designed to reduce the contractile component of resistance and improve the reliability of the measurement as muscle that is loaded slowly and passively has reduced EMG activity.³¹

The same procedure was followed, and medial rotation ROM was measured. The scapula was manually stabilized over the superior/posterior aspect with the examiner's thumb resting anteriorly over the coracoid process and clavicle. Landmarks were used according to standard shoulder goniometry principles as described by Norkin and White.³² Standardization of the reference point (zeroing) was ensured by fixating a 10-inch carpenter's level to the stationary arm of the

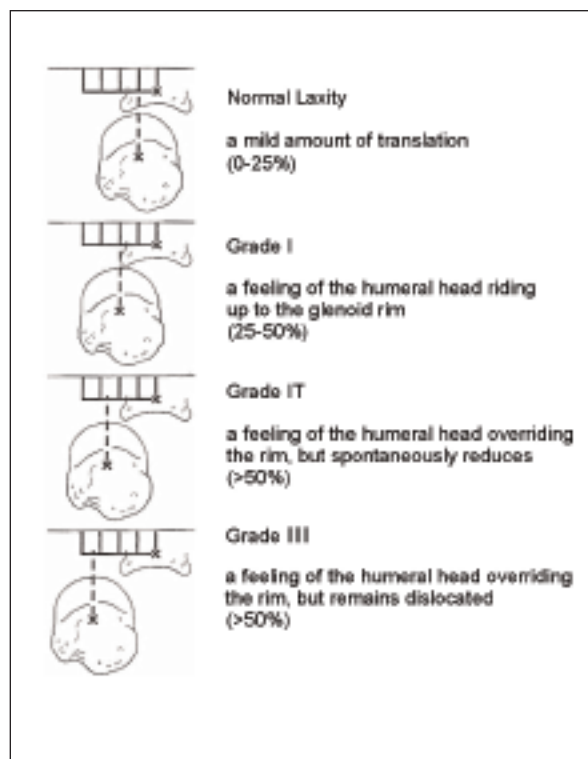


Figure 1. Hawkins

goniometer. Examiners were blinded as to which group (control vs. instability) the participants represented. The measuring examiner remained constant throughout the evaluations sessions to eliminate concerns regarding inter-tester reliability. Universal goniometry is reported to have excellent intra-tester reliability at the shoulder with ICCs of 0.85-0.99.³³

Each participant was asked to perform exercise with 5 pounds of resistance using a Hanoun wall pulley resistance system (Hanoun Medi Sport Inc., Toronto, Ont). With the superior pulley adjusted to shoulder height, they simulated a throwing motion with the measured limb (Figure 3). The participant was instructed to complete the exercise until they perceived a moderate discomfort in the shoulder area of the measured limb. The throwing activity was designed to simulate symptomatic shoulder subluxation presentation. Both lateral rotation and medial rotation measures were repeated after the symptom-provoking activity. Level of symptoms was recorded using a 10cm VAS before and after the symptom-provoking activity.

The instability group was classified as multi-directional (MDI) or uni-directional based on the presence or absence of a Sulcus Sign and Posterior Load and Shift test.^{34,35} They were assigned as multi-joint lax if three of four joints were deemed to hyperextend on passive ROM assessment, including the elbow, wrist, proximal interphalangeal joint, and knee joint. Hyperextension was defined as passive ROM at the elbow and interphalangeal in excess of 0 degrees extension, greater than 90 degrees wrist extension, and more than 3 degrees of knee extension beyond neutral. The instability group was evaluated, using the same procedure as the control group, on the affected side. Symptoms were again recorded on

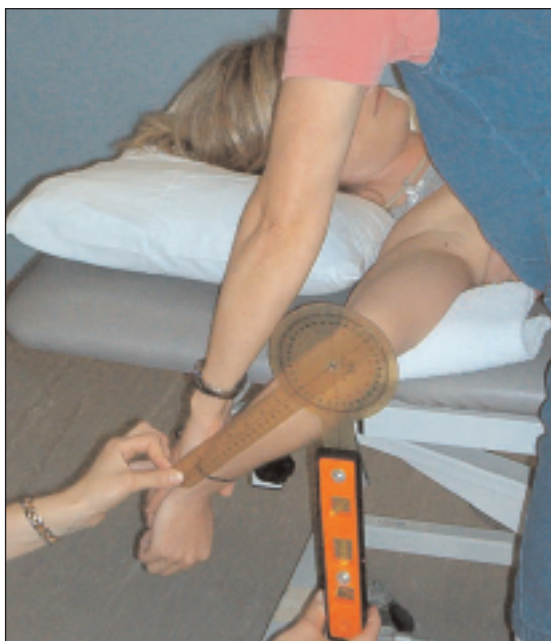

Figure 2. *Passive rotation ROM evaluation*

within groups pre and post test. Group and symptom-provoking activity interaction was evaluated. A 0.05 level of significance was used for all the analysis. Bonferonni corrections were applied to statistically significant interactions from the ANOVA.

RESULTS

Descriptive statistics for the demographics of both the control and instability group are summarized in Table 1. No statistical difference between the two groups for age, height, or mass was found.

The instability group was 35.3% male and 64.7% female, while the control group was 64.3% male and 35.7% female. Participation in overhead sporting activities was present in 25% of the instability group and 16.7% of the control group. Multi-directional classification in the instability group was 59%. The remainder, 41%, were considered uni-directional. The majority (82%) of patients with shoulder subluxation were considered to have multi-joint laxity.

Results of the two-factor ANOVA are represented in Figures 4-7. No significant difference was found between groups in lateral rotation ROM ($df =$



Figure 3. *Symptom provoking activity*

Table 1. Group comparison of descriptive data of height, mass, and age.

Descriptive Group Data						
Group	Mean Height	SE	Mean Mass	SE	Mean Age	SE
Control	174.12cm	1.91	77.09kg	2.39	25.79 years	1.11
Instability	170.76cm	2.32	75.19kg	4.26	24.53 years	1.32

Age T-value = -0.73, P-Value = 0.472; Height T-Value = -1.11, P-Value = 0.275; Mass T-Value = -0.40, P-Value = 0.696
SE, standard error

1,29, $F = 0.66$, $P = 0.422$). Also, no differences existed within groups before and after symptom-provoking activity ($df = 1,29$, $F = 0.65$, $P = 0.426$). The instability group had significantly less medial rotation ROM ($df = 1,29$, $F = 37.30$, $P = 0.000$). Both groups increased medial rotation in the post test ($df = 1,29$, $F = 11.12$, $P = 0.002$). A significantly larger ratio of lateral rotation to medial rotation ROM existed among the instability group pre ($df = 1,29$, $F = 27.30$, $P = 0.000$) and post test ($df = 1,29$, $F = 4.78$, $P = 0.0370$), and both groups decreased this ratio due to increases in medial rotation ROM post test. The control group had greater total ROM ($df = 1,29$, $F = 11.48$, $P = 0.002$) and both groups increased total ROM post test due to an increase in medial rotation ROM measures (*Figure 7*).

Visual analog symptom scale results were significantly higher in the instability group ($df = 1,29$, $F = 12.91$, $P = 0.001$) both pre and post test and increased significantly

($df = 1,29$, $F = 125.36$, $P = 0.000$) in both groups after the symptom-provoking activity (*Figure 8*).

DISCUSSION

Descriptive statistics representing the control and instability groups do not reflect any significant difference between the two groups. The control group demonstrated passive ROM characteristics consistent with those found in healthy adults in the age range reported in the inclusion criteria. Passive ROM measures in this study (*Figures 4-7*) are in excess of those reported in normative active ROM data and in excess of what was originally anticipated by the investigators, particularly for the asymptomatic control group.^{19, 24}

Sex differences between groups were noted with a greater portion of the instability group being female. A slightly higher percentage of the instability group also participat-

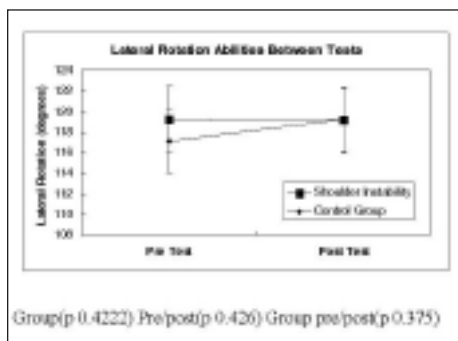


Figure 4. Lateral rotation ROM




Figure 5. Medial rotation ROM




Figure 6. Ratio of lateral to medial rotation ROM

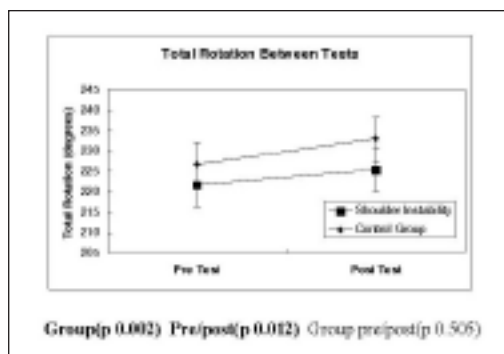


Figure 7. Total rotation ROM pre and post test

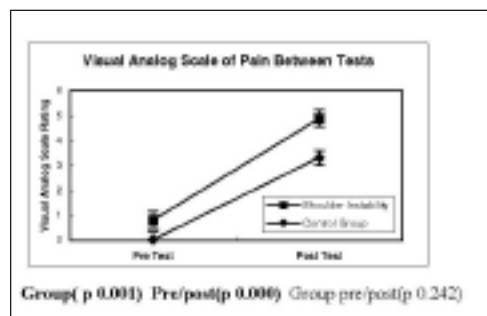


Figure 8. Visual analog scale scores pre and post test

ed in overhead sporting activities. Both of these group differences could skew the data toward larger ROM findings in the instability group.²⁴ Skewed data was not the case, with larger total ROM findings in the control group. Changes in ROM associated with limb dominance, if present, could affect results. Control shoulders were randomly assigned for evaluation and subluxation group shoulders included dominant and non-dominant symptomatic limbs.

The concept that glenohumeral hypermobility is associated with subluxation was not supported by the results of the investigation. Instead, a relationship between a lack of medial rotation passive ROM and shoulder subluxation was observed. This is also reflected in the reduced ratio of lateral rotation to medial rotation in the instability group versus the control. This altered ratio of motion may be more reflective of flexibility imbalances, often described in the clinical literature, rather than the expected hypermobility that is assumed by some authors to accompany shoulder subluxation. The Humeral Anterior Glide Syndrome described by Sahrman³⁷ or the recently coined Glenohumeral Internal Rotation Deficiency (GIRD) found in throwing athletes are consistent with this type of length/tension imbalance.³⁶ The instability group did not demonstrate overall larger ROM measures as would be expected with generalized joint laxity. With no greater total ROM noted in the instability group, a pathological shift in the functional ROM away from medial rotation may be indicated of individuals with shoulder subluxation.

Reduced length of the posterior rotator cuff musculature and the posterior shoulder capsule have been implicated in the development of internal impingement.^{38,39,40} Increased anterior translation may be necessary to allow a posterior shift in the axis of rotation and abutment of the humerus with the posterior/superior glenoid rim.

Concern existed that the presence of symptoms in the instability group may mask true passive ROM assessment due to muscle guarding or protective reaction. To reflect this variable, the assessment after a symptom-provoking activity was included. As expected, symptoms were greater in the instability group. Discomfort/pain as measured with the VAS did not seem to impact ROM findings pre-test. A trend toward a “warm-up” effect was noted in the control group after the symptom-provoking activity with ROM measures increasing. The same increase in passive ROM was not observed in the instability group post-test. Symptoms may prevent flexibility increases associated with activity in this pathological group. No loss of ROM was observed with increased scores on the VAS post-test. Symptoms may have to be in excess of those provoked in the study to impact ROM findings.

Increased passive ROM or excessive flexibility may indeed not provide any supportive evidence of shoulder subluxation. Instead, flexibility imbalances may be more indicative of, and even causative in, the development of low-grade shoulder instability. While most (82%) of the participants in the study were classified with multi-joint laxity, certainly not all were. A high degree of flexibility may exist at one joint and not at others. No universally inclusive relationship between multi-joint laxity and shoulder subluxation existed. A slight majority (59%) of the instability group were classified as multi-direction instability. Perhaps the presence of a ROM imbalance combined with a certain degree of local flexibility is jointly causative in the development of shoulder subluxation. The fact that many of our instabilities only subluxated in one direction supports the possible necessity of an imbalance or even cumulative microtraum in etiology of shoulder subluxation.

Reduced length of posterior shoulder structures (rotator cuff, capsule, posterior deltoid) may, in part, be responsible for restriction of motion and reduced medial rotation in subjects with shoulder subluxation. Treatment techniques directed at lengthening these structures and restoring normal joint length/tension balance may be indicated in this client population. Future study in this area could look at PROM findings in shoulder instability of greater degree. Interventions could be analyzed to determine effectiveness at restoring a more neutral flexibility balance and symptom response. Also, electromyographic activity which would provide information on the active component muscle force that restricts the ROM was not measured. In future work, EMG activity could help ascertain the cause of the change in ROM.

CONCLUSION

In summary, no overall increase in passive rotation ROM was observed among shoulder subluxators. Loss of medial rotation ROM was noted in the subluxation group compared to the asymptomatic control group. An imbalance of lateral to medial rotation ROM may be associated with symptomatic shoulder subluxation. The presence of mild to moderate symptoms ($\leq 6/10$ on VAS) does not seem to alter passive rotation ROM findings of the shoulder but may limit the ability to increase ROM associated with activity. Imbalance in lateral to medial ROM findings may be more clinically relevant in screening for shoulder subluxation than assessment of total rotation ROM of the shoulder or classification of generalized joint hypermobility. Findings may have implications for treatment technique selection with shoulder subluxation clients.

REFERENCES

1. Cofield RH, Irving JF. Evaluation and classification of shoulder instability with special reference to examination under anesthesia. *Clin Orthop.* 1987;223:32-43.
2. Jobe FW, Pink M. Classification and treatment of shoulder dysfunction in the overhead athlete. *J Orthop Sports Phys Ther.* 1993;18:427-432.
3. McFarland EG, Kim TK, Park HB, et al. The effect of variation on the diagnosis of multidirectional instability of the shoulder. *J Bone Joint Surg Am.* 2003; 85: 2138-2144.
4. Wilk KE, Andrews JR, Arrigo CA. The physical examination of the glenohumeral joint: Emphasis on the stabilizing structures. *J Orthop Sports Phys Ther.* 1997;25:330-389.
5. Garth WP, Allman FL, Armstrong WS. Occult anterior subluxations of the shoulder in noncontact sports. *Am J Sports Med.* 1987;15:579-582.
6. Magarey M, Jones M. Clinical diagnosis and management of minor shoulder instability. *Aust J Physiother.* 1992;38:269-279.
7. Oulette H, Kassarian, Tretreault P, Palmer W. Imaging in the overhead throwing athlete. *Semin Musculoskelet Radiol.* 2005;9:316-333.
8. Jobe FW, Tibone JE, Pink MM, et al. The Shoulder in Sports. In: Rockwood CA, Matsen FA eds. *The Shoulder.* Philadelphia, PA: WB Saunders Co; 1996:1214-1238.
9. Chaipat L, Palmer W. Shoulder magnetic resonance imaging. *Clin Sports Med.* 2006;25:371-386.
10. Harryman OT, Sidles JA, Clark JM. Translation of the humeral head on the glenoid with passive glenohumeral motion. *J Bone Joint Surg.* 1990;72:1334-1343.
11. McGlynn FJ, Caspari RB. Arthroscopic findings in the subluxing shoulder. *Clin Orthop.* 1984;183:173-178.
12. Pappas AM, Gross TP, Kleinmann PK. Fluoroscopic evaluation for subtle shoulder instability. *Am J Sports Med.* 1992;20:548-552.
13. Barden JM, Balyk R, Raso VJ, et al. Dynamic upper limb proprioception in multidirectional shoulder instability. *Clin Orthop.* 2004;420:181-189.
14. Forewell LA, Cornaham H. Proprioception during manual aiming in individuals with shoulder instability and controls. *J Orthop Sports Phys Ther.* 1996;23:111-119.
15. O'Brien SJ, Warren RF, Schwartz E. Anterior shoulder instability. *Orthop Clin North Am.* 1987; 18: 395-408.
16. Pappas AM, Gross TP, Kleinmann PK. Symptomatic shoulder instability due to lesions of the glenoid labrum. *Am J Sports Med.* 1983;11:279-288.
17. Bigliani LU, Codd TP, Connor PM, et al. Shoulder motion and laxity in the professional baseball player. *Am J Sports Med.* 1997;25:609-613.
18. Kvitine RS, Jobe FW. The diagnosis and treatment of anterior instability in the throwing athlete. *Clin Orthop.* 1993;291:107-123.
19. Leighton JR. Flexibility characteristics of three specialized skill groups of champion athletes. *Arch Phys Med Rehabil.* 1957;38:24-28.
20. Wilk KE, Arrigo C. Current concepts in the rehabilitation of the athletic shoulder. *J Orthop Sports Phys Ther.* 1993;18:365-378.
21. Reid DC, Sabae LA, Chepeha JC. Anterior shoulder instability in athletes: Comparison of isokinetic resistance exercises and electromyographic feedback re-education program – a pilot program. *Physiother Can.* 1996;4:251-256.

-
22. Hawkins RJ, Abrams JS. Impingement syndrome in the absence of rotator cuff tear (stages I and II). *Orthop Clin North Am.* 1987;18:373-382.
 23. Beach ML, Whitney SL, Dickoff-Hoffman SA. Relationship of shoulder flexibility strength and endurance to shoulder pain in competitive swimmers. *J Orthop Sports Phys Ther.* 1992;16:262-268.
 24. Boon AJ, Smith J. Manual scapular stabilization: Its effect on shoulder rotational range of motion. *Arch Phys Med Rehabil.* 2000;81:978-983.
 25. Boon DC, Azen SP. Normal range of motion of joints in male subjects. *J Bone Joint Surg.* 1979;61:756-759.
 26. Gunal I, Kose N, Erdogan O, et al. Normal range of motion of the joints of the upper extremity in male subjects with special reference to side. *J Bone Joint Surg.* 1996;78:1401-1404.
 27. Chessworth BM, MacDermoid JC, Roth JH, Patterson SD. Movement diagram and "end-feel" reliability when measuring passive lateral rotation of the shoulder in patients with shoulder pathology. *Phys Ther.* 1998;78:593-601.
 28. MacDermid JC, Chessworth BM, Patterson S, Roth JH. Intratester and intertester reliability of goniometric measurement of passive lateral shoulder rotation. *J Hand Ther.* 1999;12:187-192.
 29. Laudner KG, Stanek JM, Meister K. Assessing posterior shoulder contracture: The reliability and validity of measuring glenohumeral horizontal adduction. *J Athl Train.* 2006;41:375-380.
 30. Tzannes A, Paxinos A, Callahan M, Murrell GA. An assessment of the interexaminer reliability of tests for shoulder instability. *J Shoulder Elbow Surg.* 2004;13:18-23.
 31. Wilkinson A. Stretching the truth. A review of the literature on muscle stretching. *Aust J Physiother.* 1992;38:283-287.
 32. Norkin CC, White JD. *Measurement of Joint Motion: A Guide to Goniometry.* Philadelphia, PA: F.A. Davis Co; 1985.
 33. Riddle DL, Rothsstein JM, Lamb RL. Goniometric reliability in a clinical setting. Shoulder measurements. *Phys Ther.* 1987;67:668-673.
 34. Hawkins RJ, Mohtadi NG. Clinical evaluation of shoulder instability. *Clin J Sports Med.* 1991;1:59-64.
 35. Neer CS. *Shoulder Reconstruction.* Philadelphia, PA: W.B. Saunders Co.; 1990.
 36. Burkhart SS, Morgan CD, Kibler WB. The disabled throwing shoulder: Spectrum of pathology part I: Pathoanatomy and biomechanics. *Arthroscopy.* 2003;19:404-420.
 37. Sahrman SA. *Diagnosis of Movement Impairment Syndromes.* St. Louis, MO: Mosby; 2002.